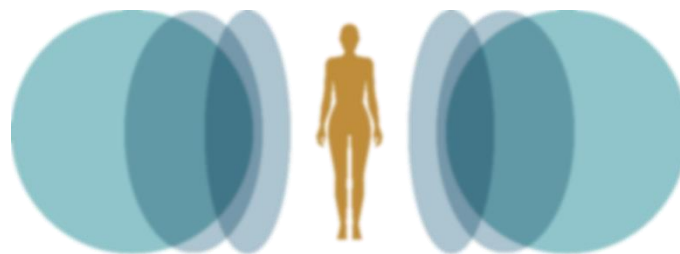


Todo acerca de la Nariz: Estética y Seguridad



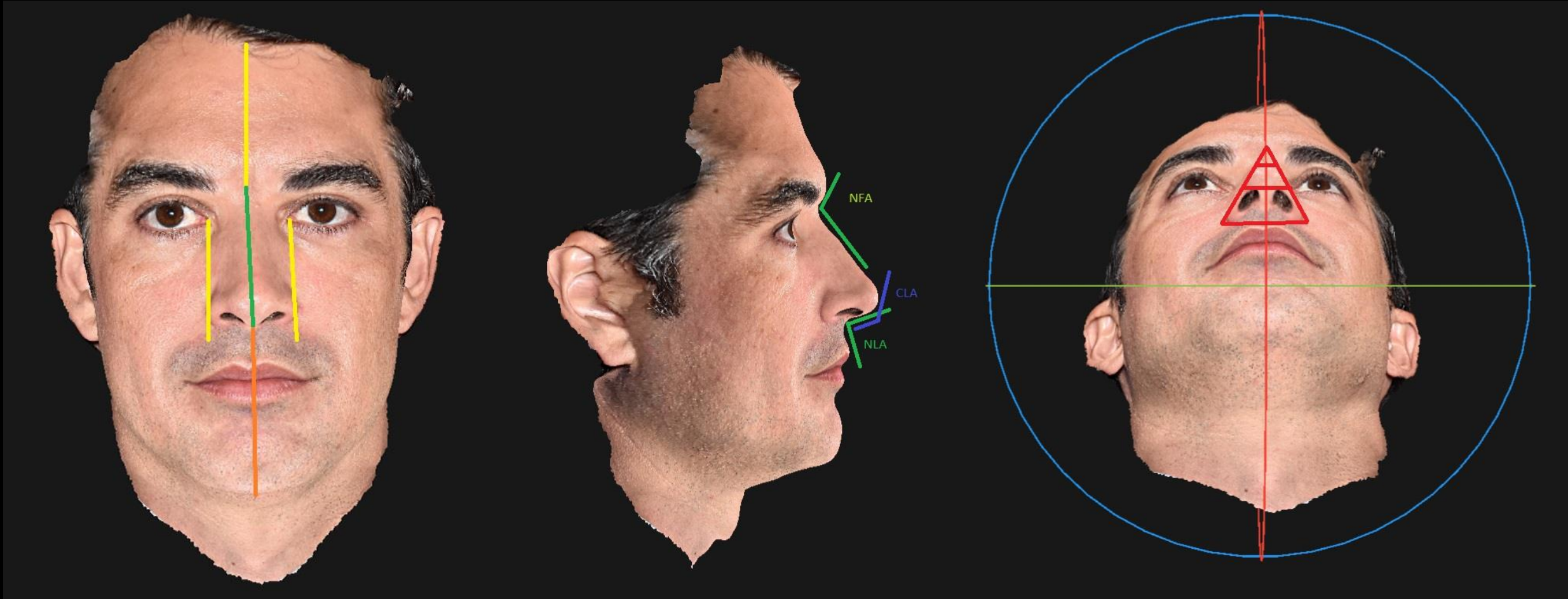
Sebastian Torres MD

Nariz:

- Organo Respiratorio
- Principal atributo estético facial



Estética NASAL



Correcciones Requeridas

- Funcional
- Estéticas



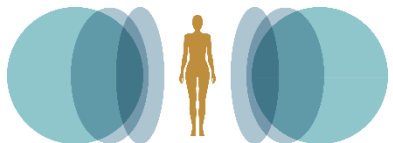

Correcciones Nasales Estéticas

- Quirúrgicas
- Médicas



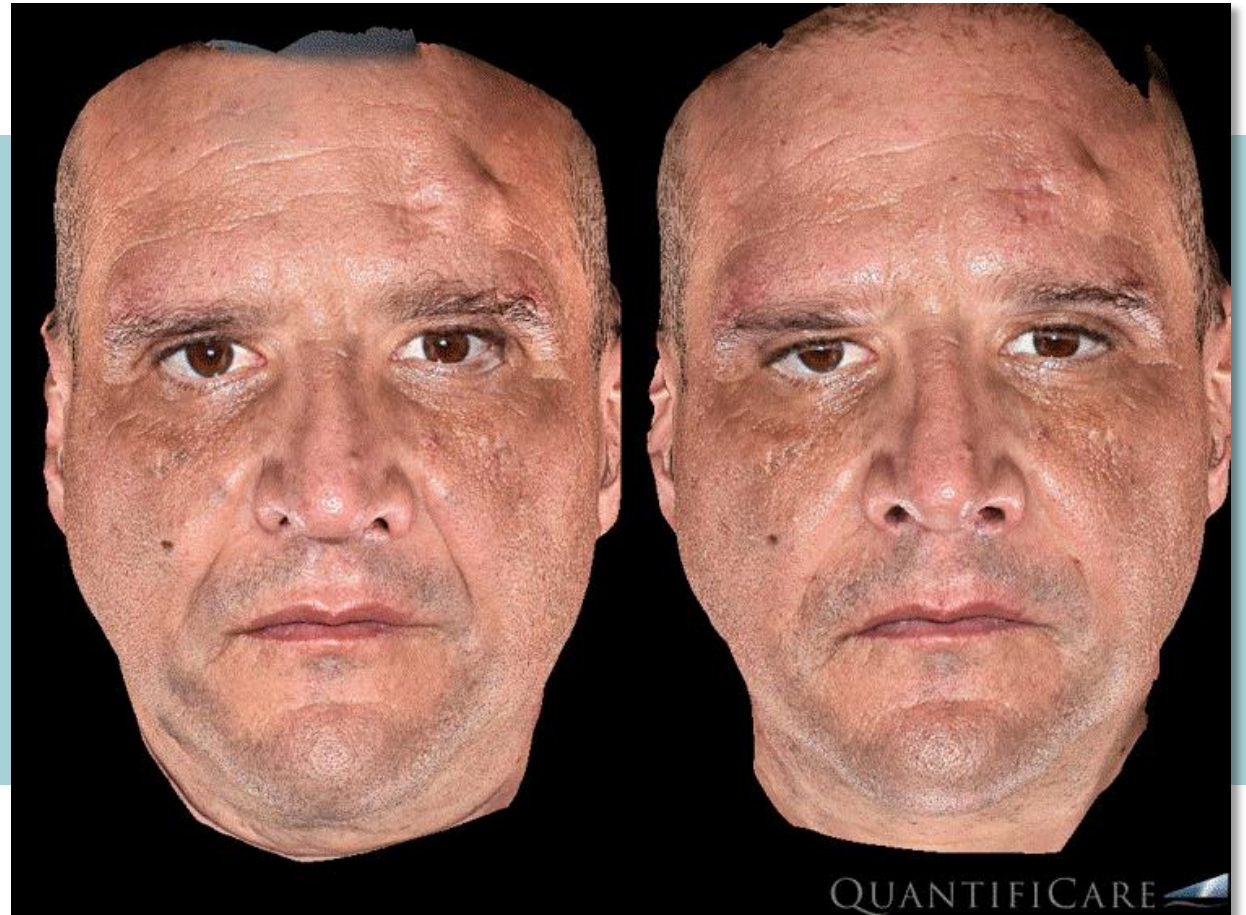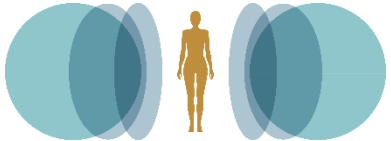
Procedimientos Nasaes Quirúrgicos

Más frecuente en
Jóvenes...



Procedimientos Nasales Médicos

Más frecuentes en
Adultos...



Rinofiller

- Infiltración de rellenos para modificar la estructura nasal interna/externa por motivos estéticos o funcionales
- Supone adecuado conocimiento de las estructuras anatómicas relacionadas



Braccini (2008)

Nueva alternativa de restructuración de los tejidos blandos nasales

REV LARYNGOL OTOL RHINOL.
2008;129,4:1-6.

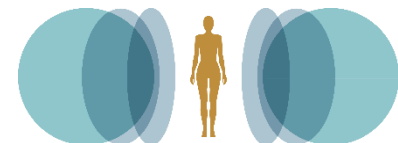
CHIRURGIE PLASTIQUE

A R T I C L E O R I G I N A L

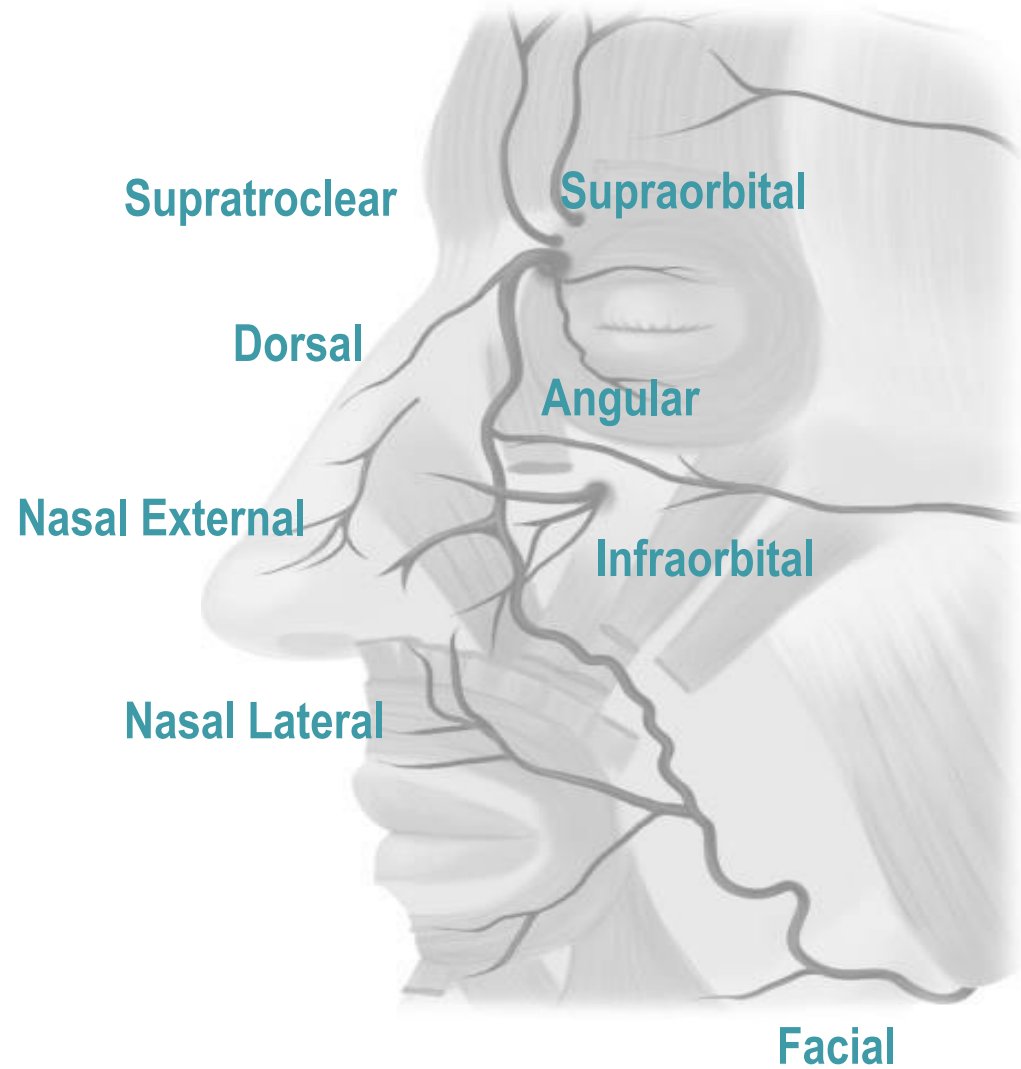
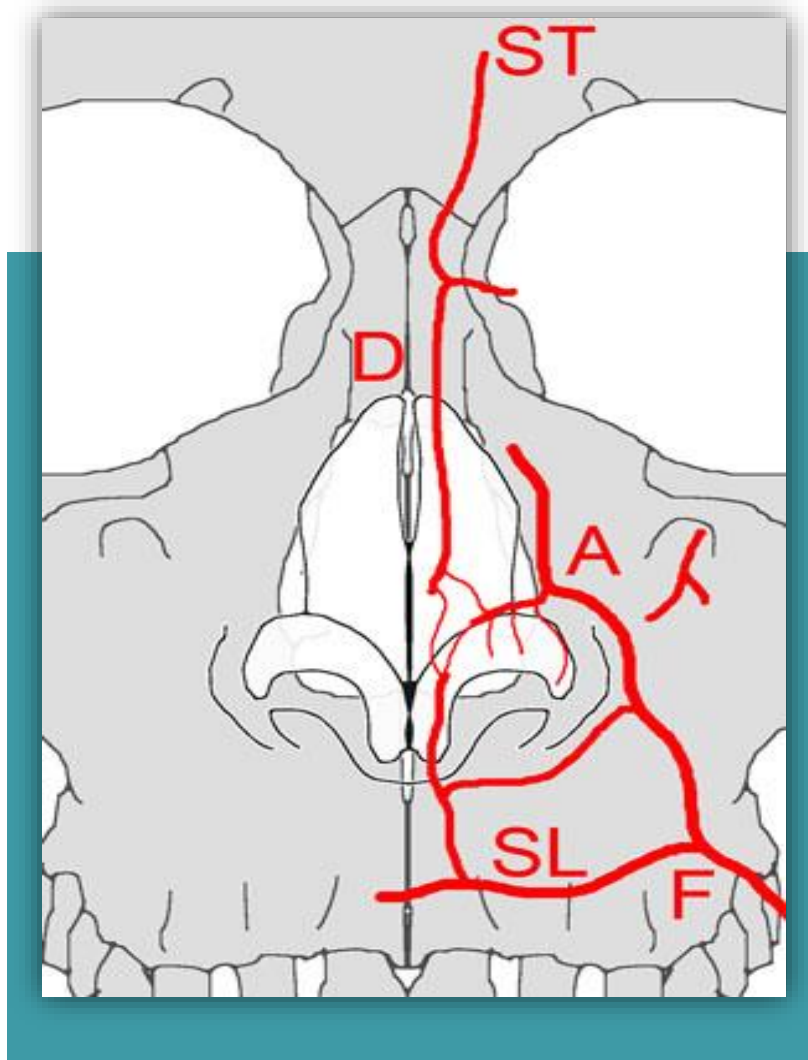
**La rhinoplastie médicale : de l'usage de la toxine botulique
et des produits de comblement pour un remodelage
atraumatique du nez**

Medical rhinoplasty: Rationale for atraumatic nasal
modelling using botulinum toxin and fillers

Braccini F. ¹
Dohan Ehrenfest D. M. ²
(Nice)

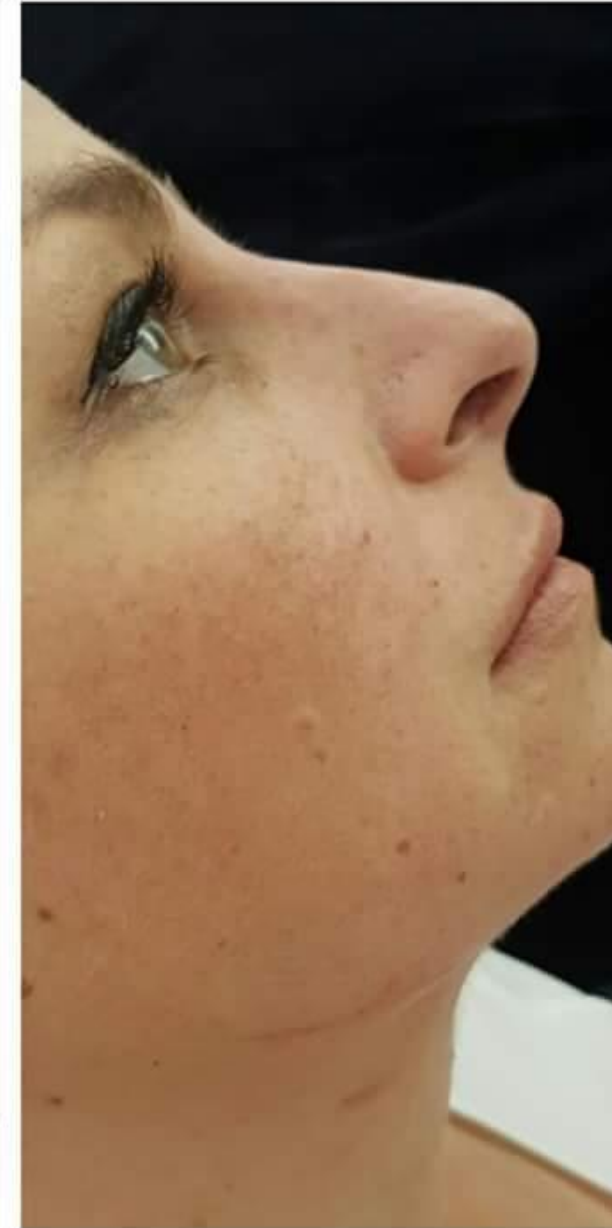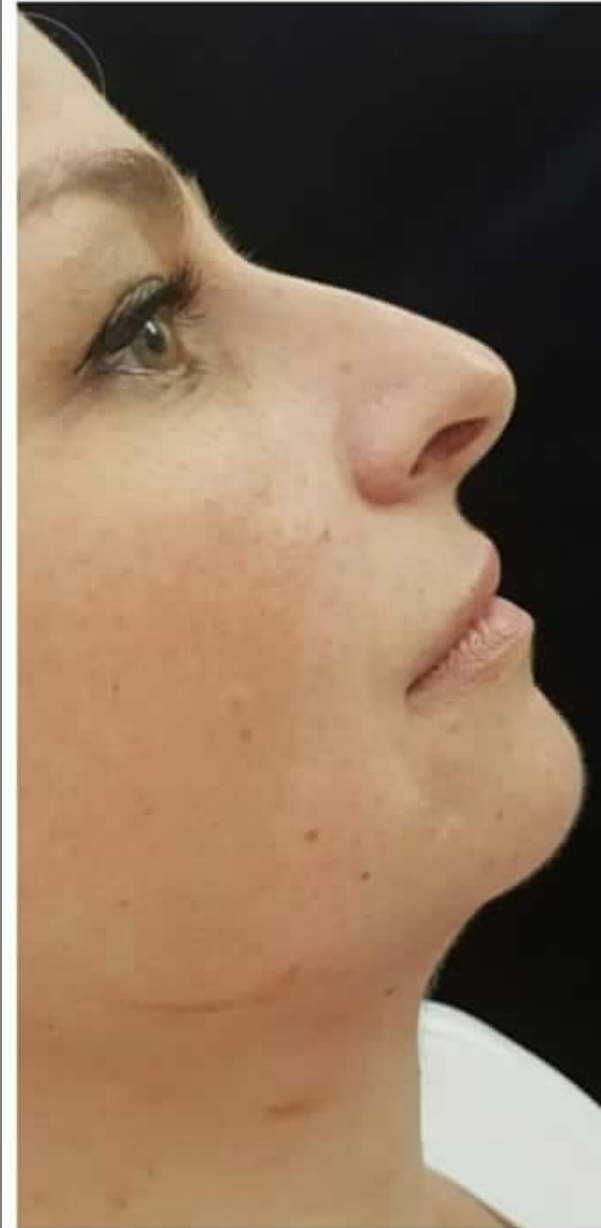


Anatomía

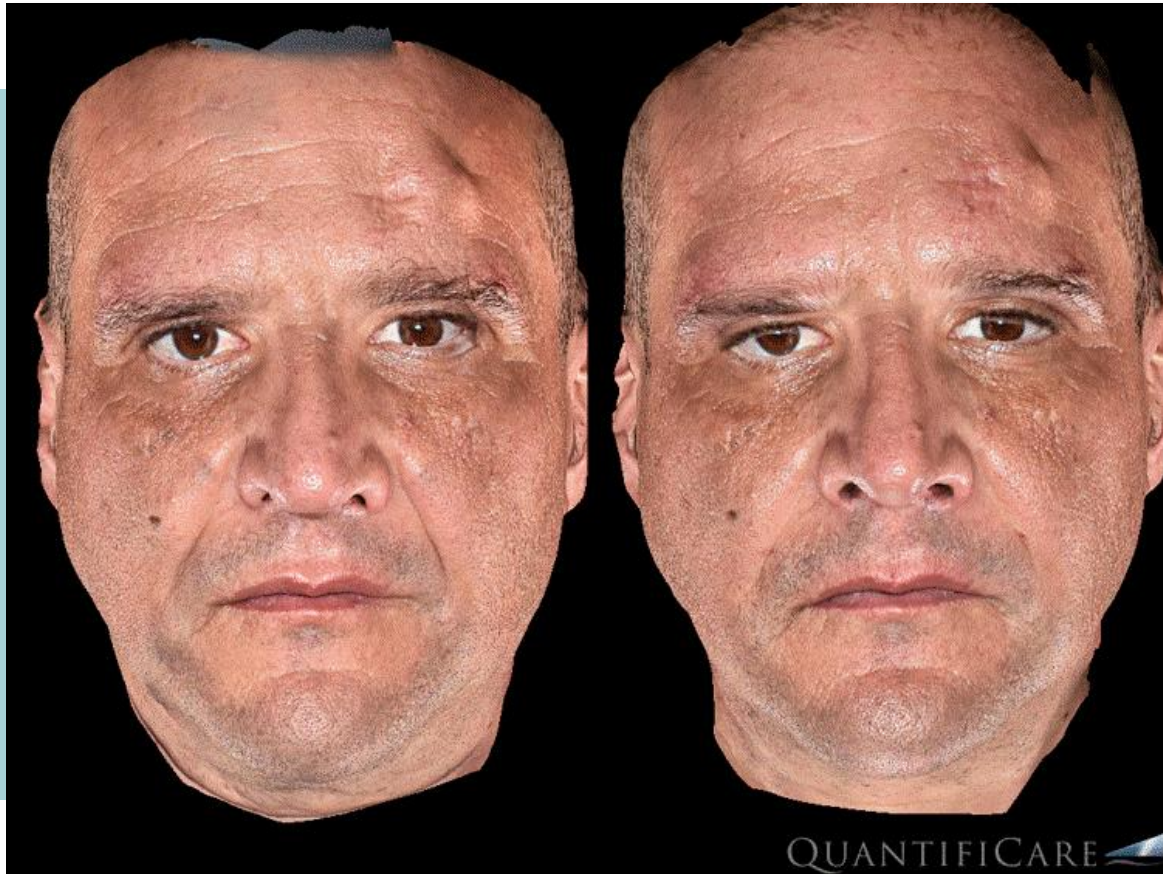
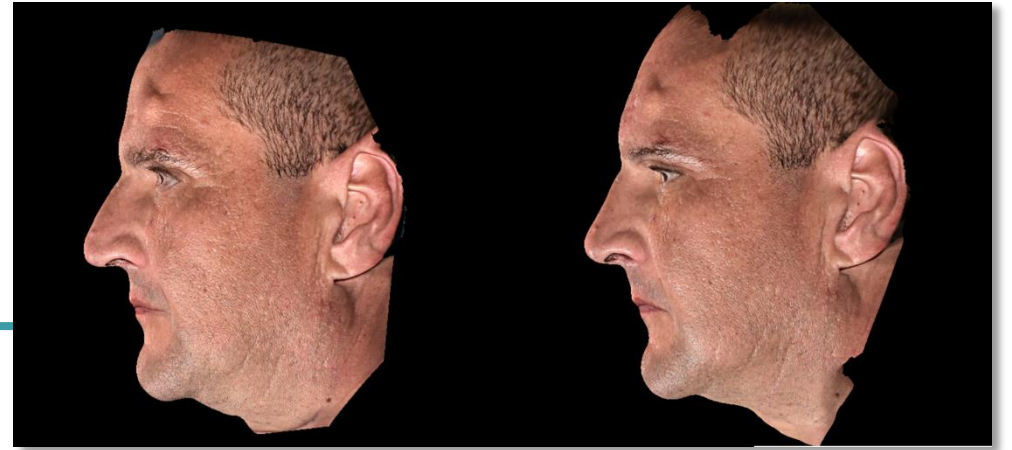

Indicaciones

- Pz refractorio cirugía
- Ausencia de disfunción aérea
- Pequeños gibos dorsales
- Déficit moderados en proyección punta
- Asimetría Líneas estéticas dorsales
- Pequeños defectos post rinoplastía
- Envejecimiento Nasal



Artículo Envejecimiento Nasal 2017



SciTeMed
Publishing Group

REVIEW

**Archives of Otorhinolaryngology
Head & Neck Surgery**

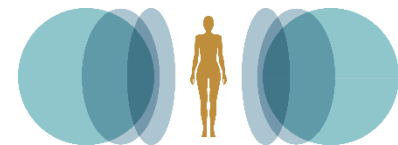
Nasal Aging and Rejuvenation

Sebastian Torres, MD*

Plastic and Aesthetic Surgery Private Practice, Santiago, Chile

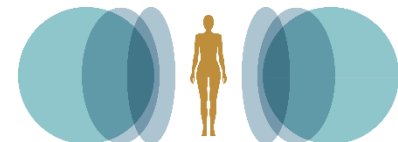
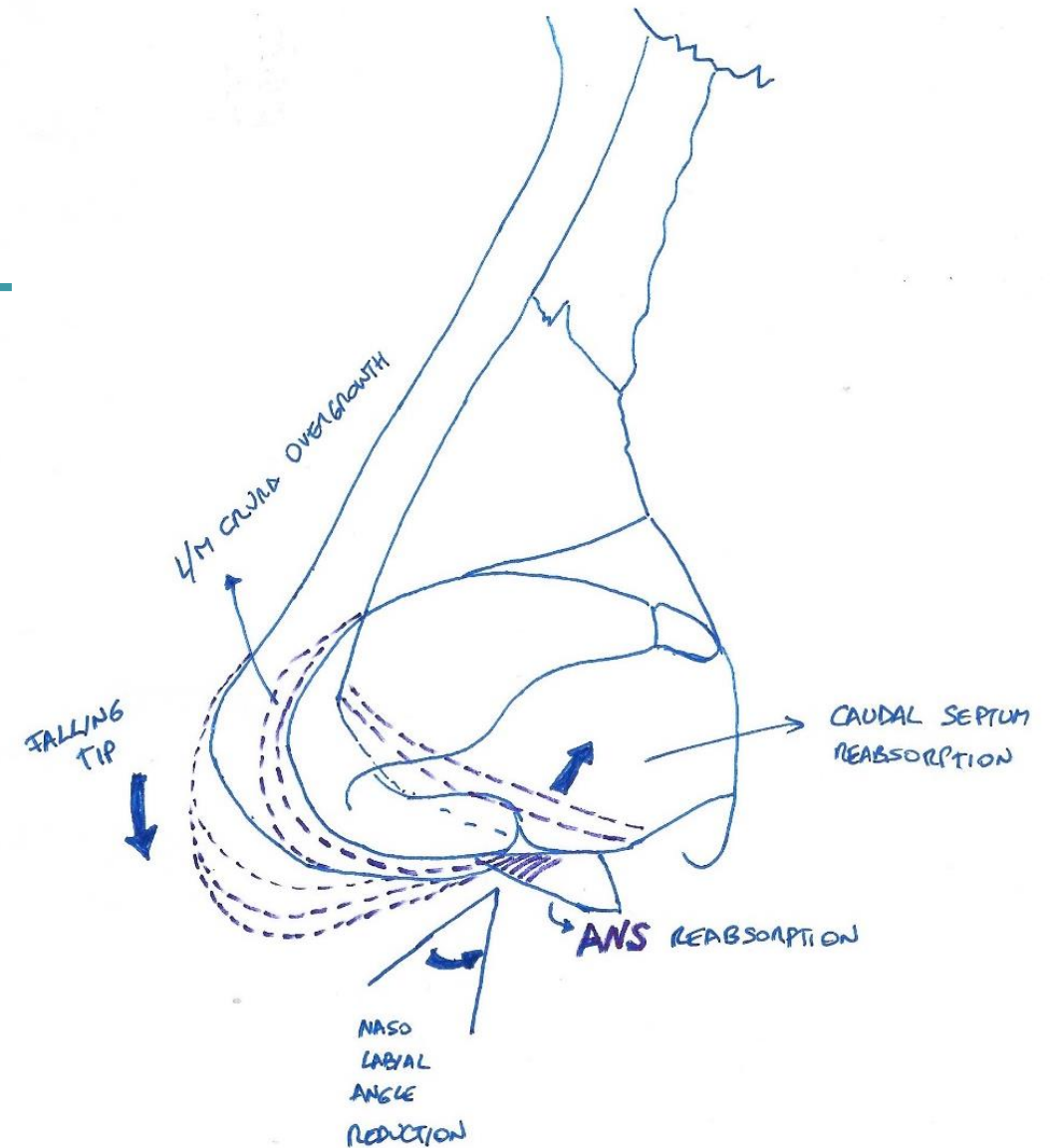
Abstract

Bone, cartilage, muscles, subcutaneous layer, and skin form nasal tissues. Anatomy and physiology in young and normal individuals have been extensively studied and published; nevertheless, little importance has been focused on the concept of nasal aging and its related rejuvenation procedures. The former is a continuous process that may alter patient aesthetics, functionality, and self-esteem. Although corrections of this condition were not available in the past, modern science has developed minimally invasive alternatives that have attracted the interests of patients and medical community. The author presents a review of the principal aspects of nasal aging and an algorithm to approach nasal rejuvenation.



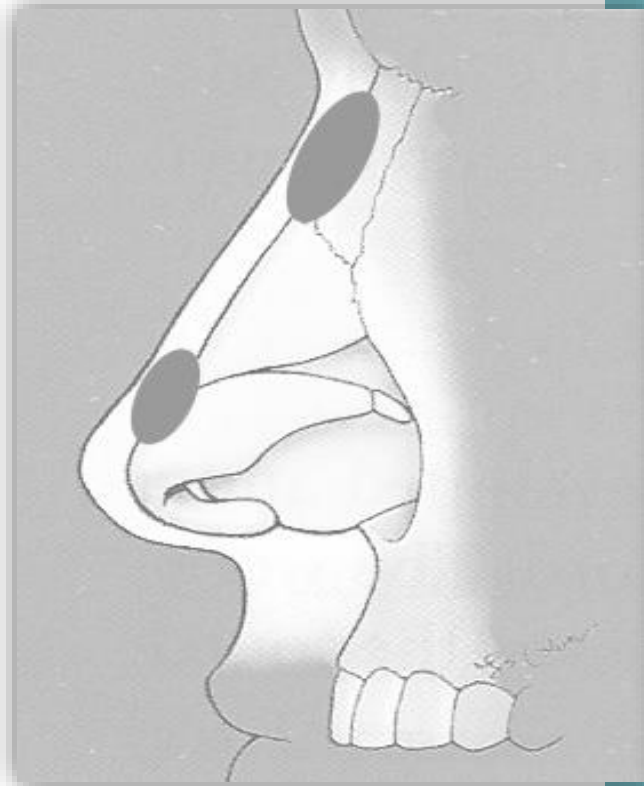
Envejecimiento Nasal Fisiopatología

- Caída de la Punta
- Reducción ANL
- Esqueletonización
- Rinofima
- Crecimiento Vascular
- Perdida definición Supratip

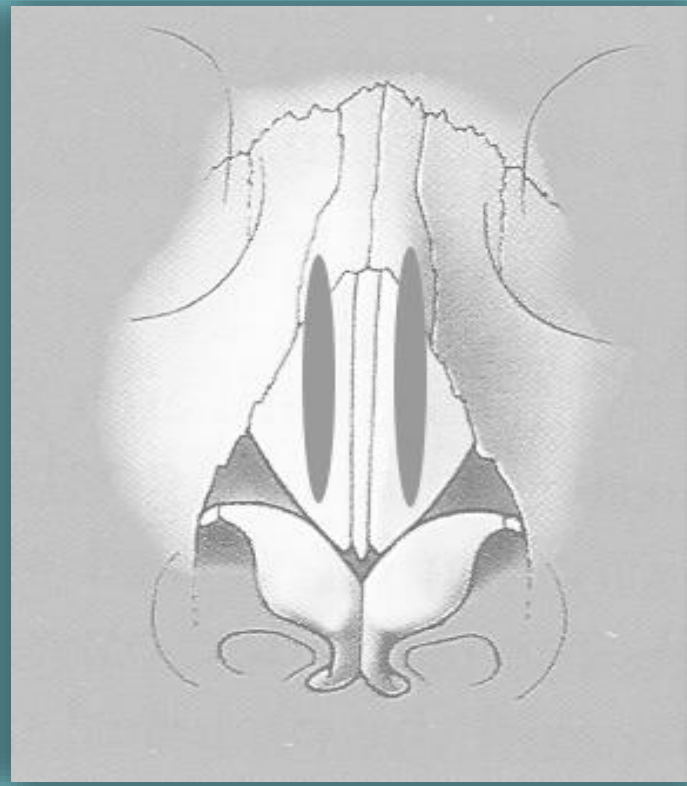




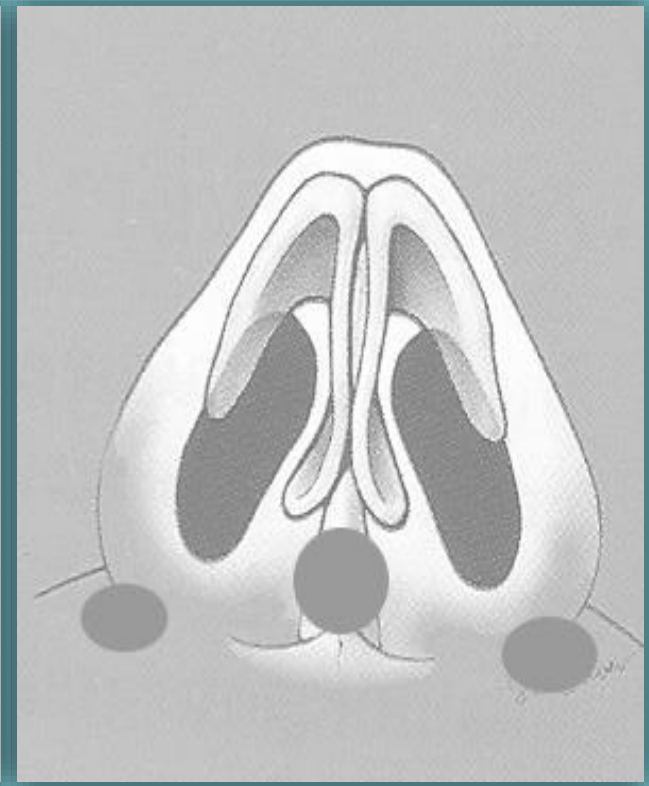
Áreas Tratamiento



Dorso-punta



Líneas estéticas dorsales



Proyección Basal

Contraindicaciones

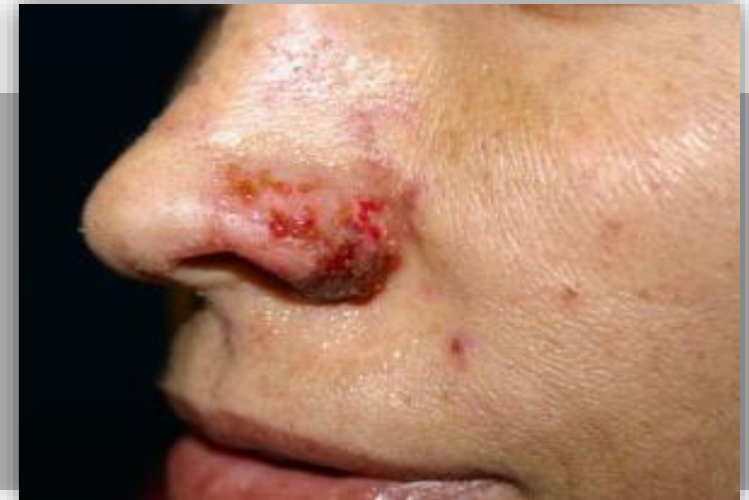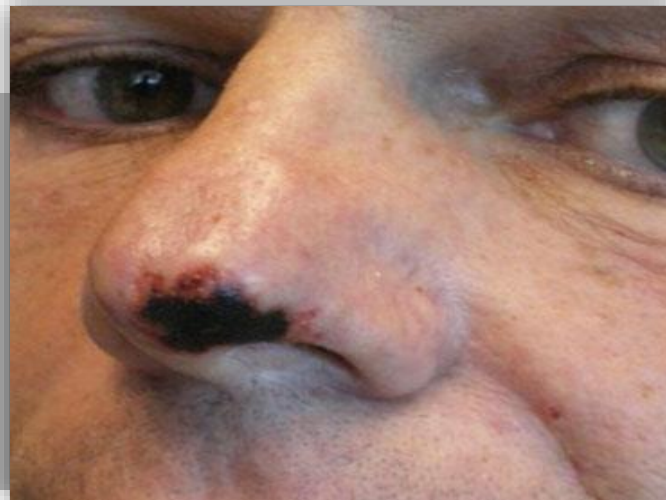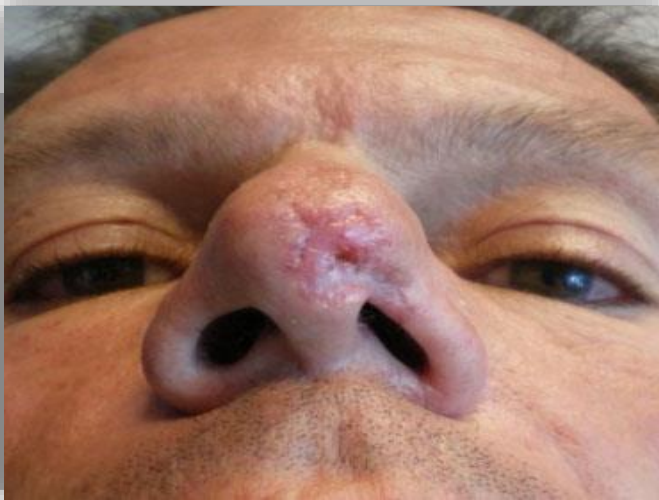- Expectativas Irreales
- Disfunción aérea
- Deseos de Nariz más pequeña
- Infección del área
- Dermatitis o Trauma Reciente
- Médico Inexperto



Complicaciones

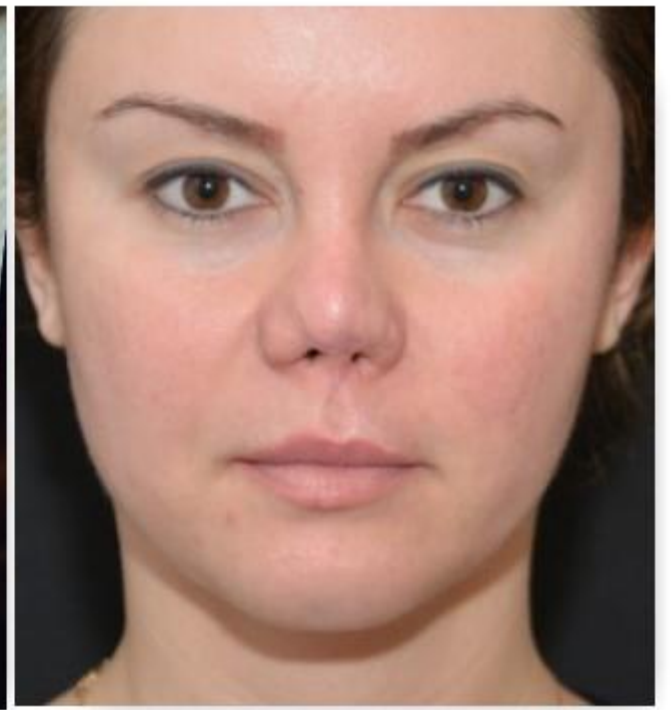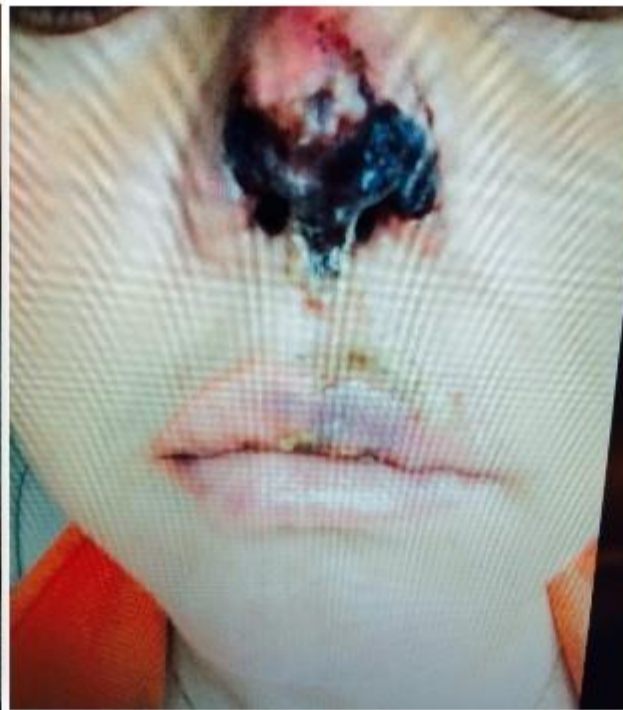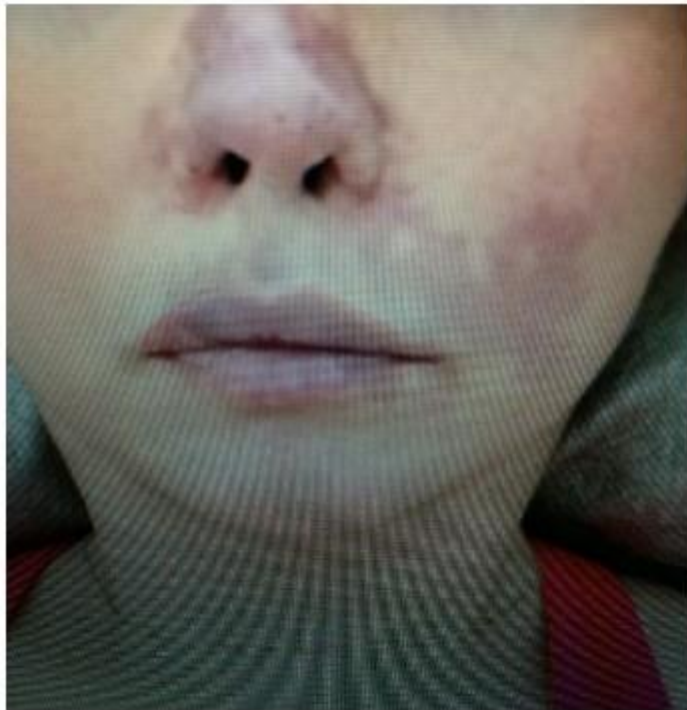- Dolor
- Nódulos
- Alergias
- Granuloma
- Sobrecorrección
- Migración
- Efecto Tyndall (HA superficial)
- Infección
- Parálisis
- Reactivación Biofilm (PMNT)

Vasculares!!!

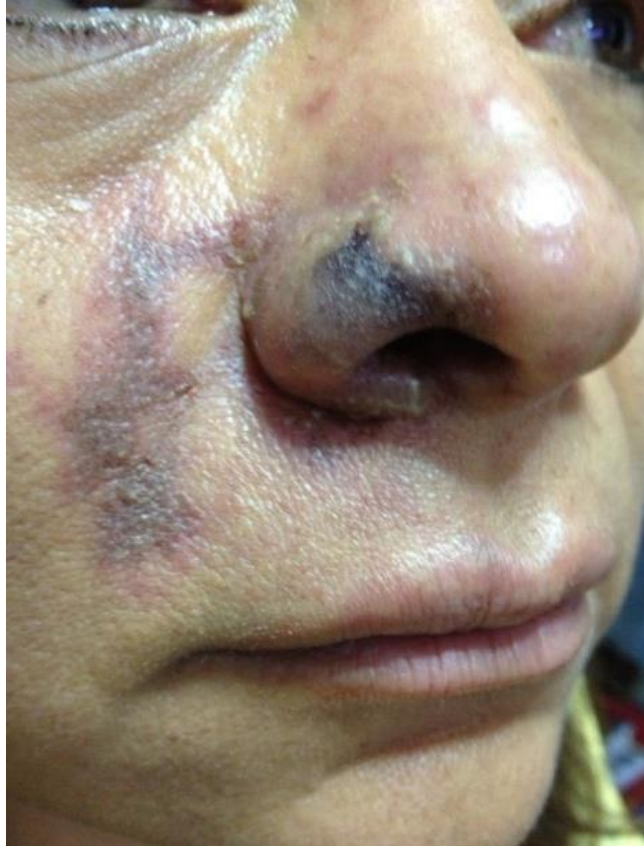

Complicaciones Vasculares Nasales

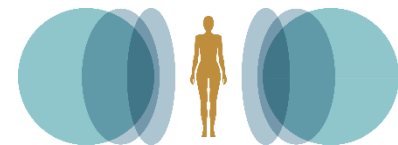
- Intra vascular
- Extra vascular (Síndrome **Compartimental**)



Siempre ten presente
Complicaciones
Vasculares



- Aspirina
- Cremas con Nitrato (TNT) 2%
- Calor
- Masajes
- Hialuronidasa
- Cámara Hiperbarica
- Alprostadiil 120 $\mu\text{g}/\text{d}$



El mejor tratamiento: Prevención



Técnica

- Inyecciones profundas
- Infiltración Retrograda
- Espectativas Realísticas
- Materiales
- Cantidad
- Viscocidad
- Presión



Técnicas

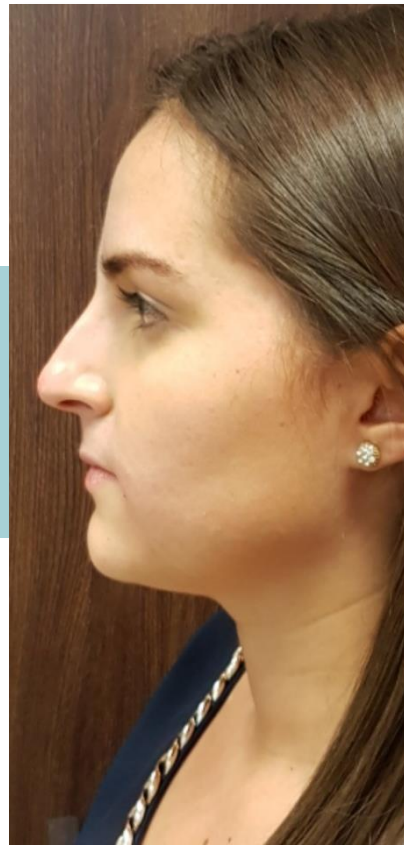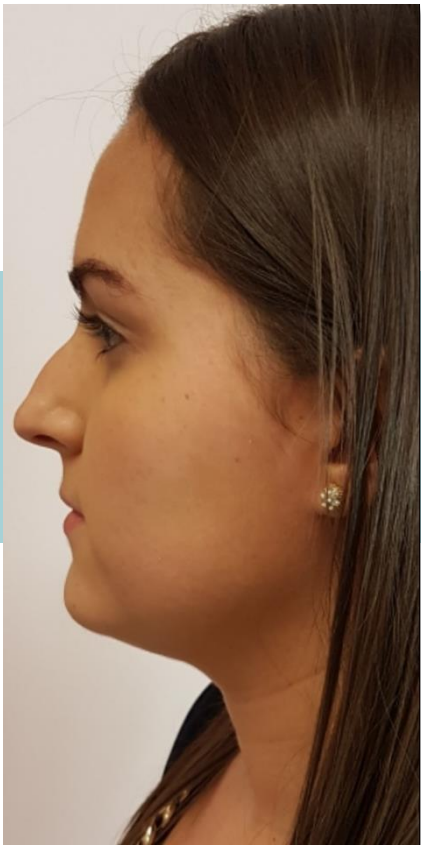- Vasoconstricción
- Mejorar, sin obsesionarse
- Preferir Canulas
- Consentimiento Informado
- Kit Emergencia
- Pedir ayuda



Torres (2015)

No touch Nose Technique :

Correcciones Nasales mejores y más precisas en todos los grupos etarios



NASAL VOLUMETRIC REMODELLING WITH THE AID OF A NEW, STABILISED HYALURONIC ACID DERMAL FILLER

***Sebastian Torres**

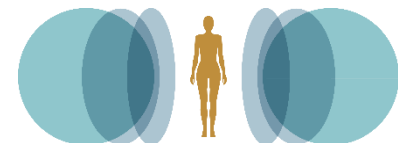
Department of Plastic Surgery, Humanitas Clinic, Catania, Italy

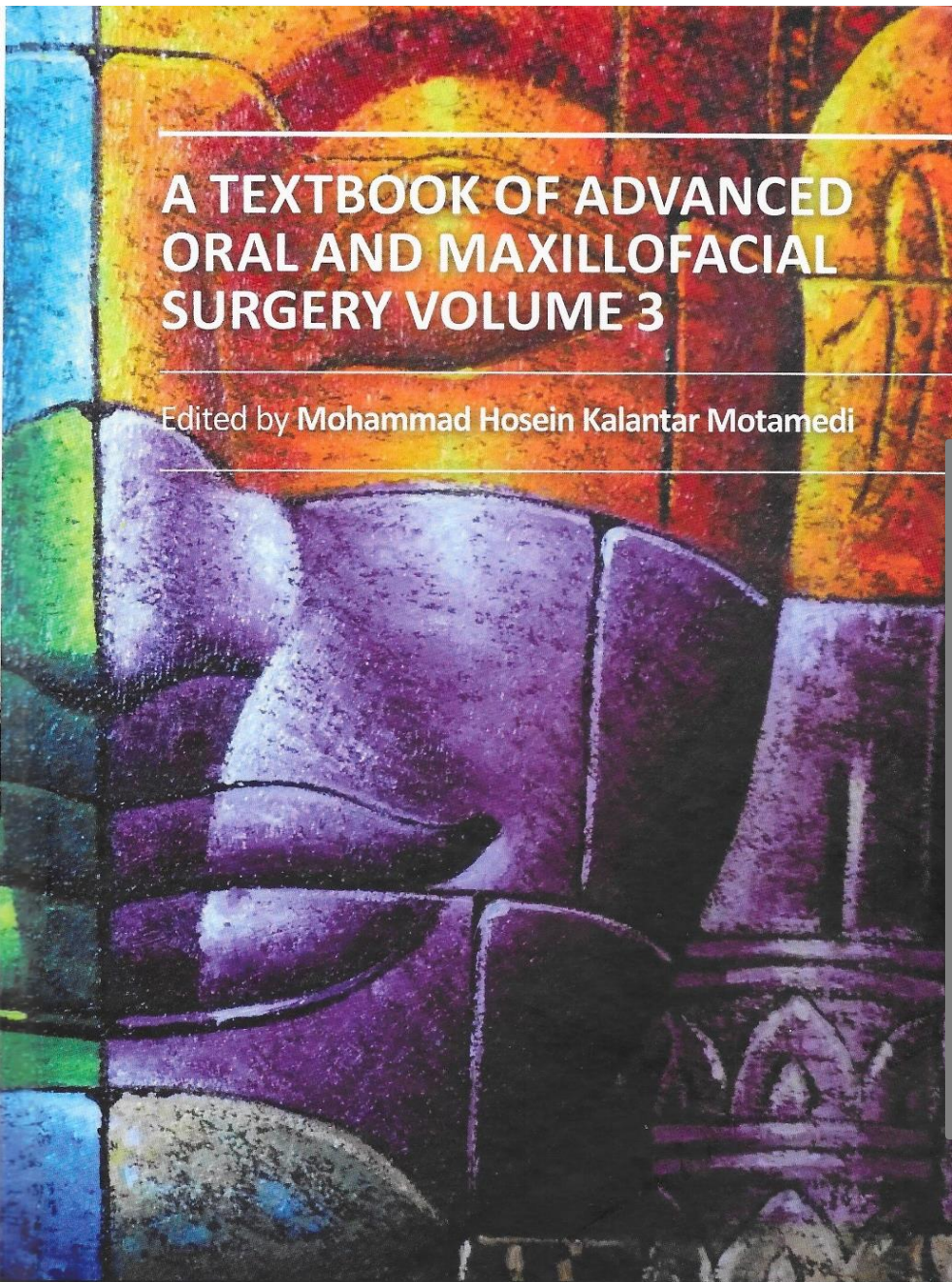
**Correspondence to info@sebastiantorresmd.com*

Disclosure: The author has previously given workshops for Bohus Biotech, but is not commercially linked to the company.

Received: 06.07.15 **Accepted:** 11.08.15

Citation: EMJ Dermatol. 2015;3[1]: - .





**A TEXTBOOK OF ADVANCED
ORAL AND MAXILLOFACIAL
SURGERY VOLUME 3**

Edited by **Mohammad Hosein Kalantar Motamedi**

INTECH

LIBRO Técnica Torres

August 2016

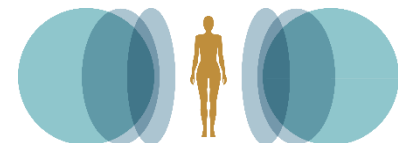
Chapter 30

Management of Common Complications in Rhinoplasty and Medical Rhinoplasty

Sebastian Torres and Tito Marianetti

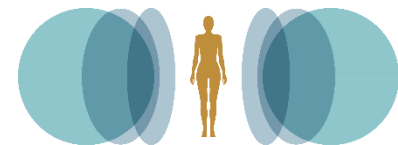
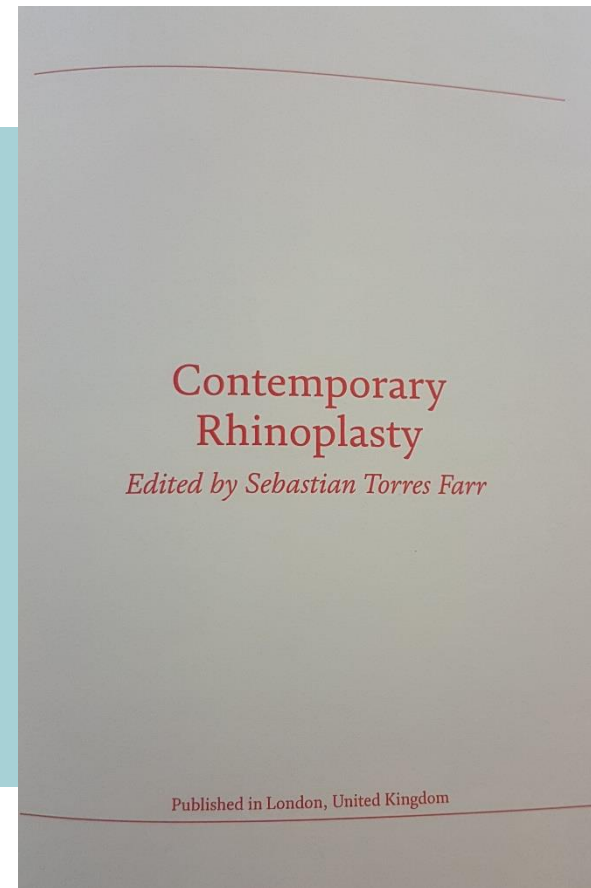
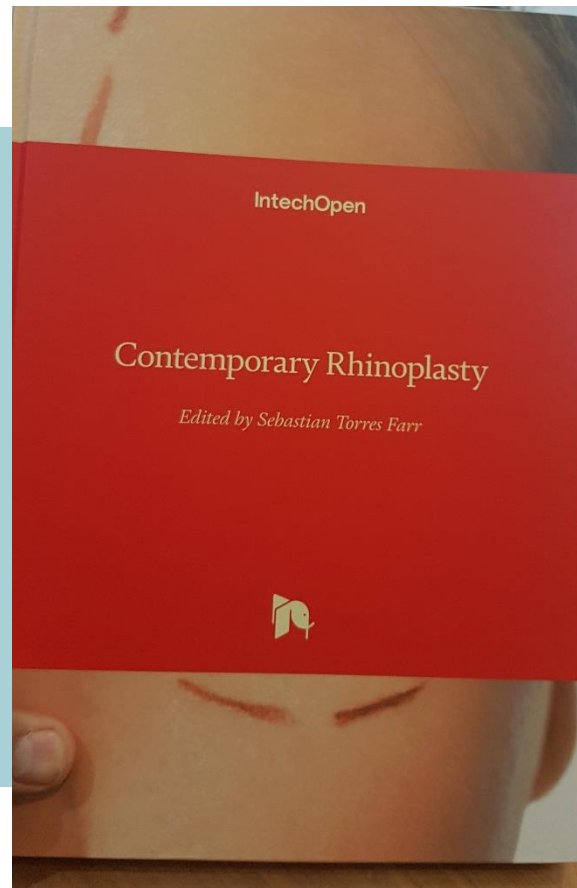
Additional information is available at the end of the chapter

<http://dx.doi.org/10.5772/63130>



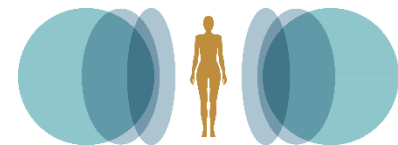
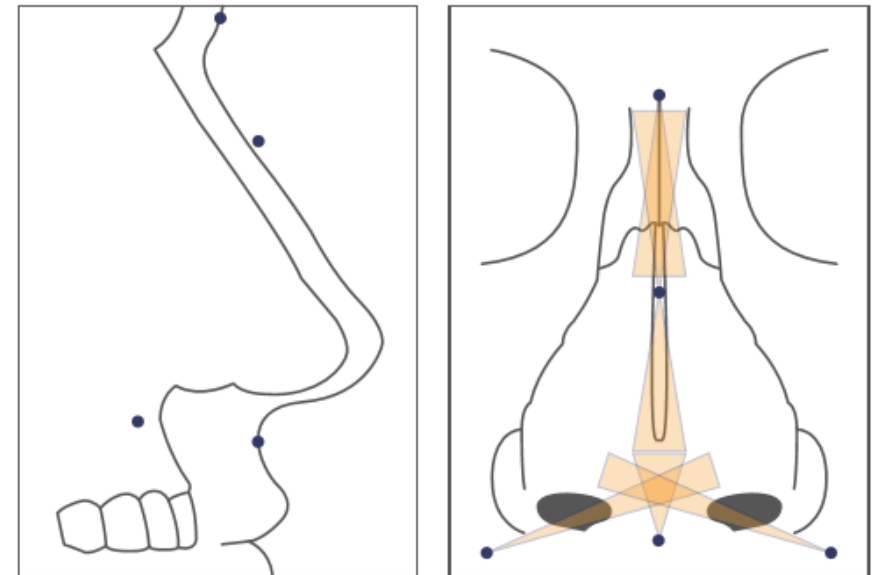
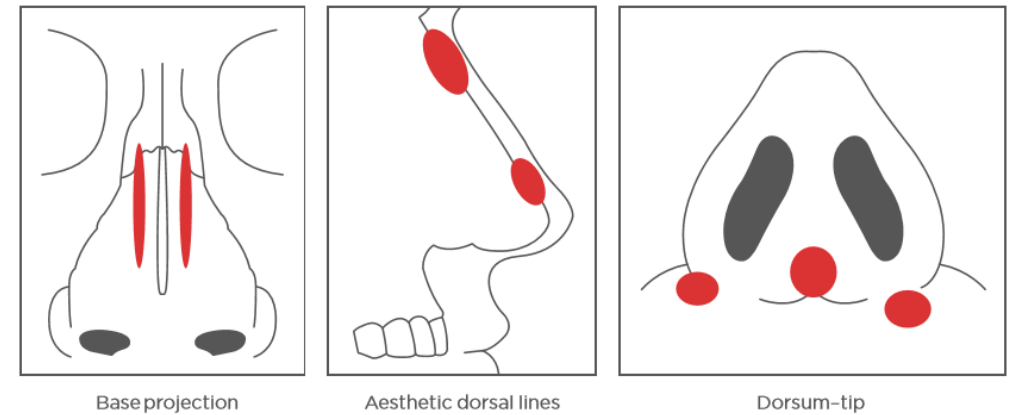
Contemporary Rhinoplasty (2019)

Editor Sebastian Torres Farr. IntechOpen. December 2019. ISBN:978-1-83968-028-1, Print ISBN:978-1-83968-027-4



Técnica No Touch Nose

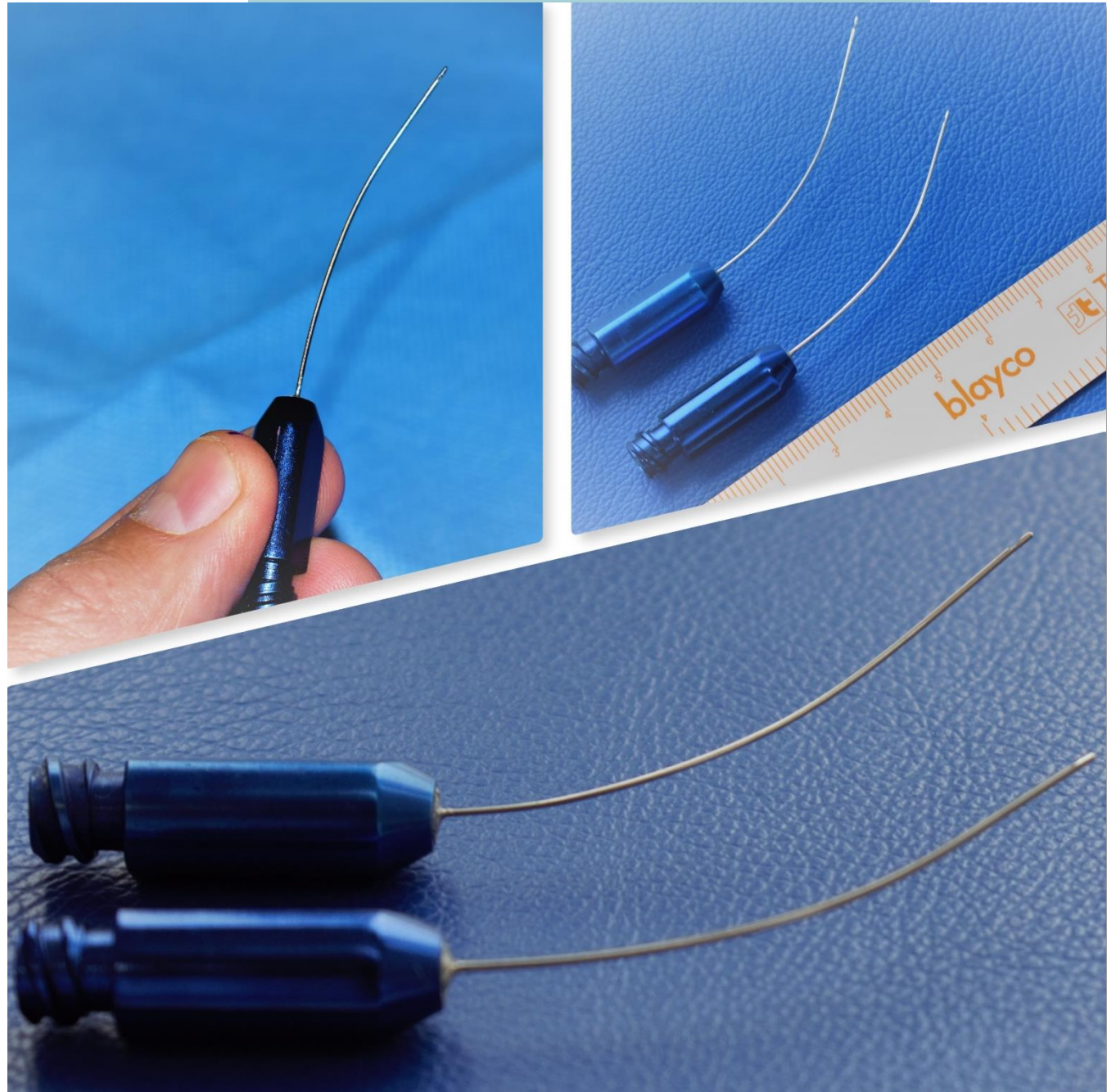
- Puntos de acceso distantes - menor trauma
- Cánulas Curvas - Intuitivas
- Injerto Trípode volumétrico →
Modificaciones dramáticas ANL
- Menores complicaciones



Cánulas Curvas Torres

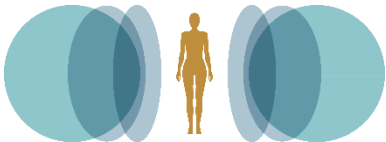
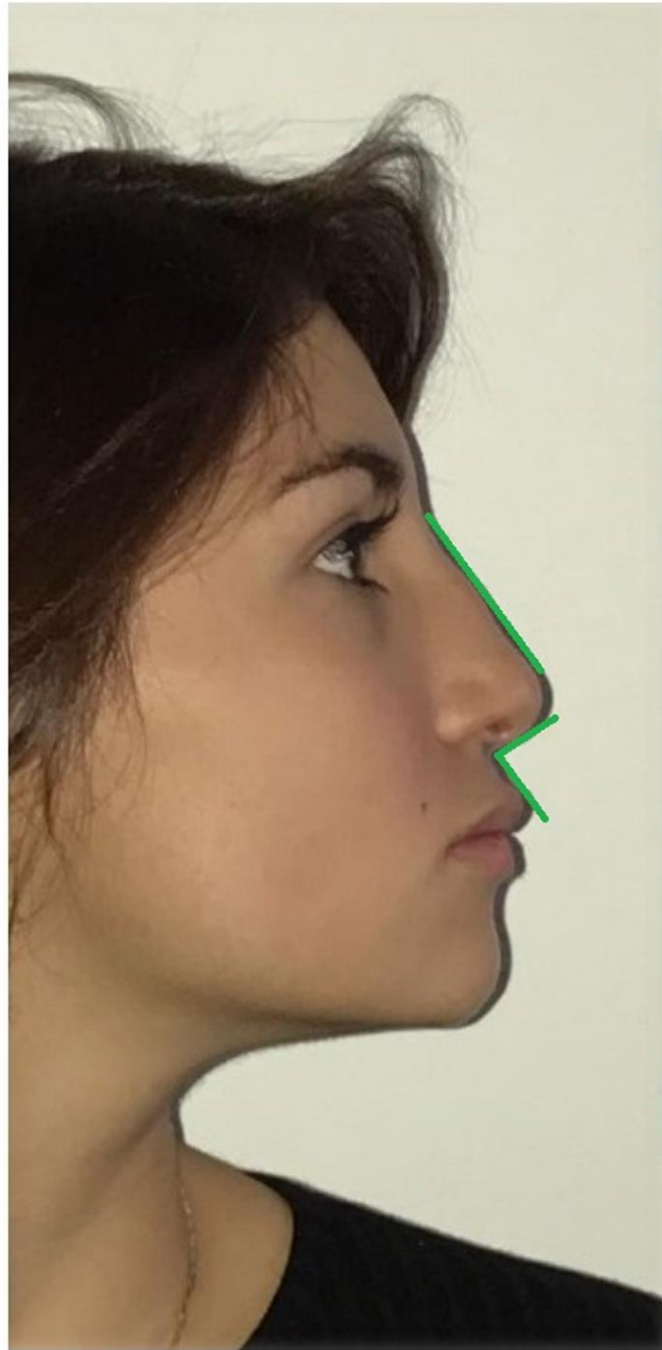
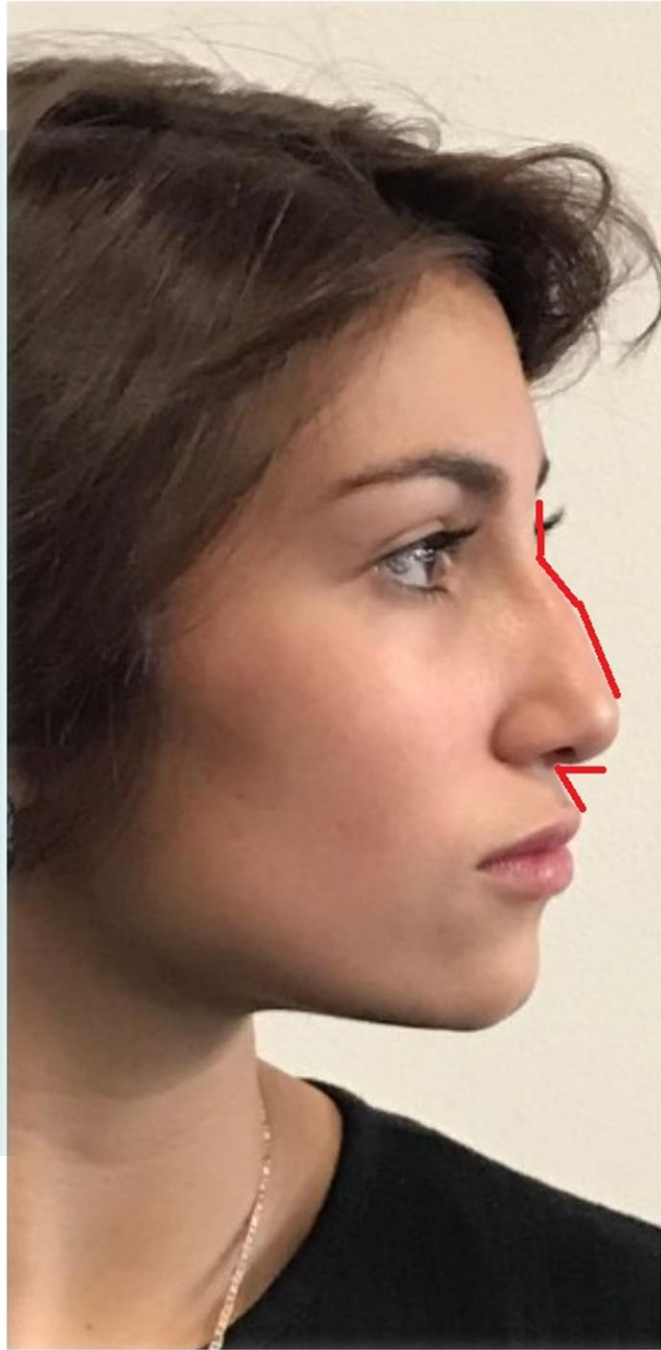
- Diseño Patentado USA
- Sigue Contornos Faciales / Nasaes
- Menor Trauma / Complicaciones (vascular)
- Flujo Laminar
- Permite posicionamiento Injerto Trípode

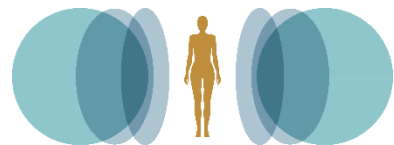
Volumétrico





TORRES

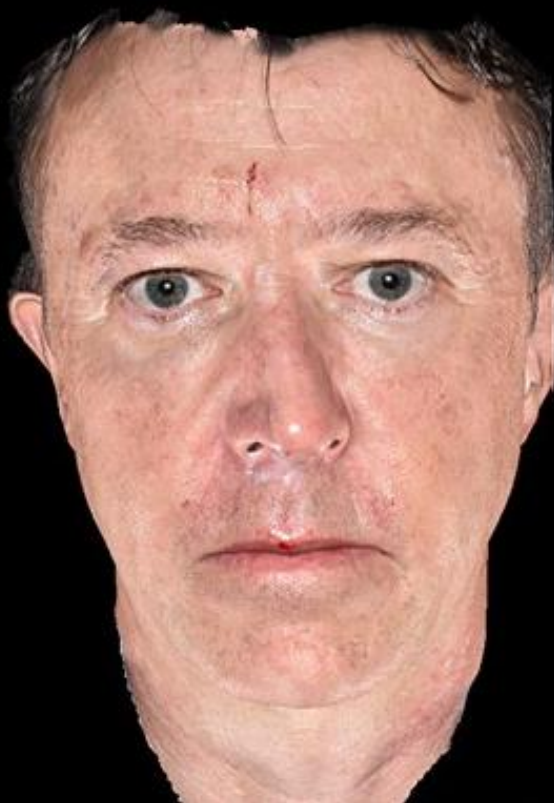



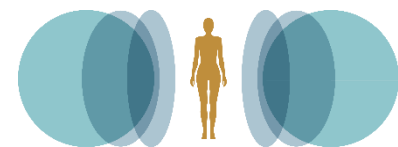

Before



After



After with volume

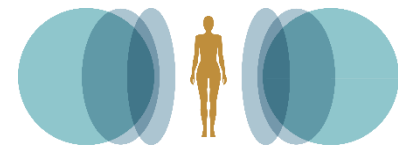
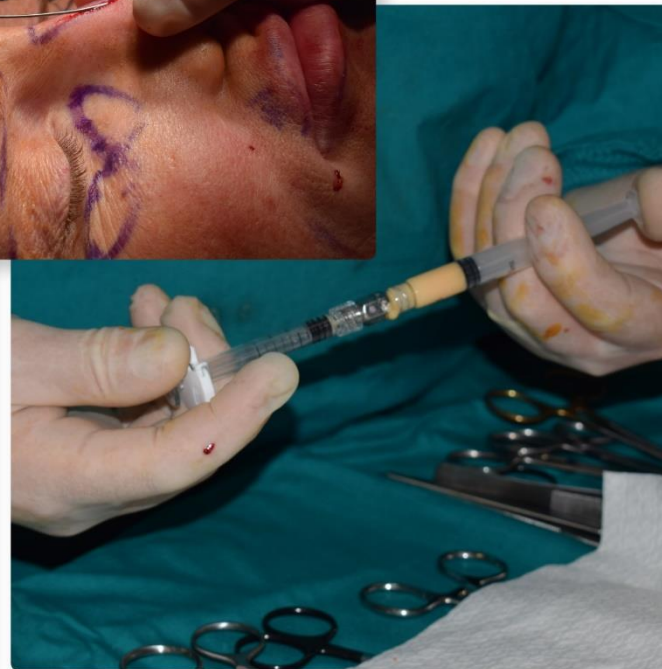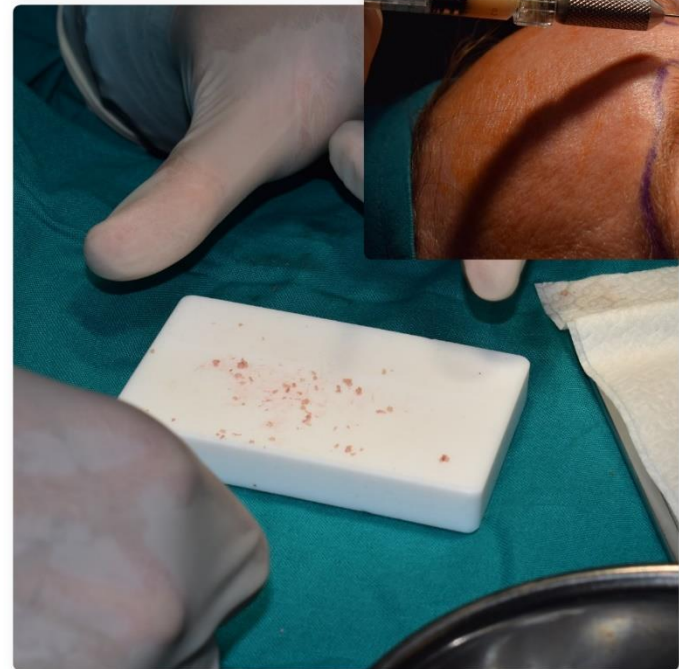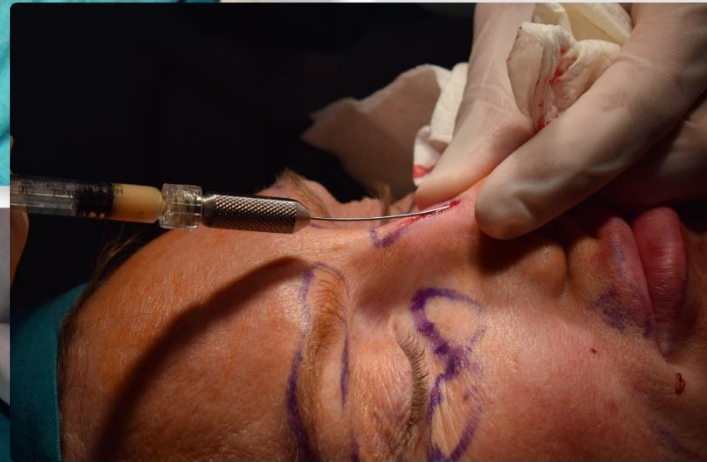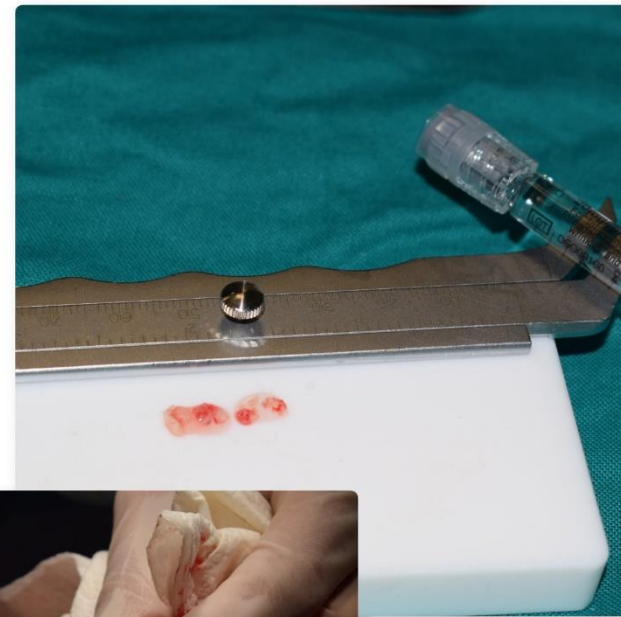


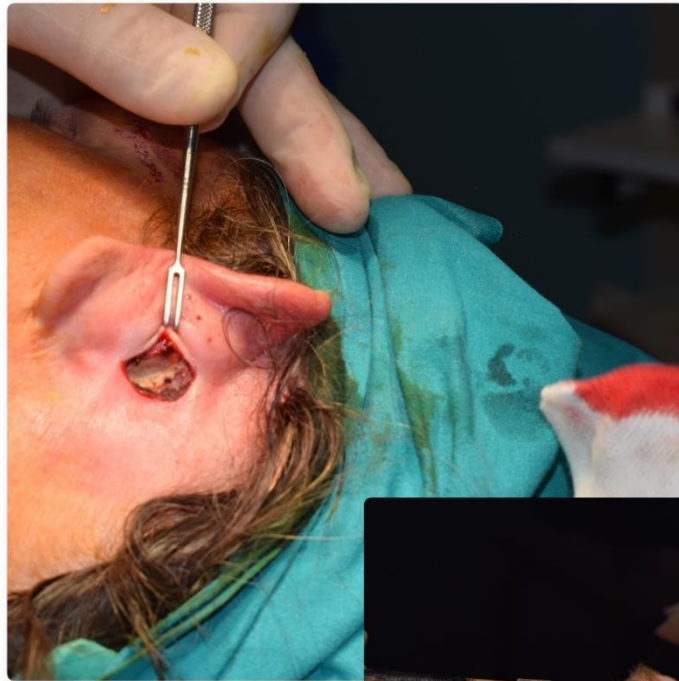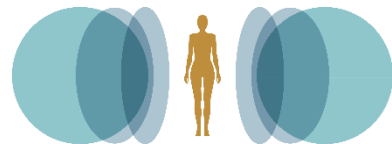
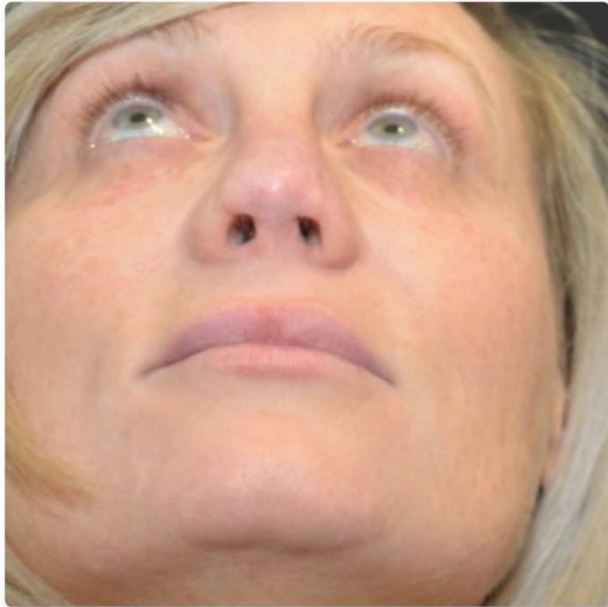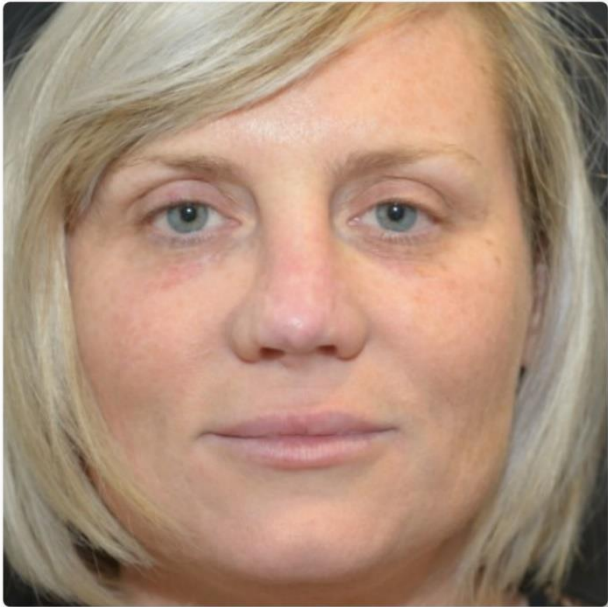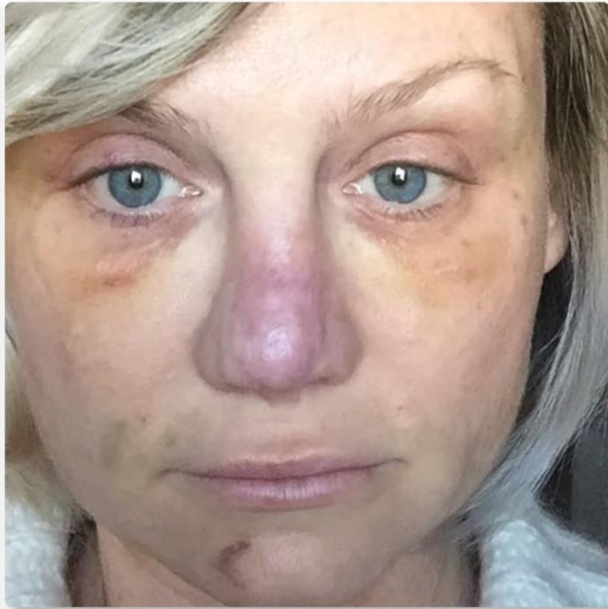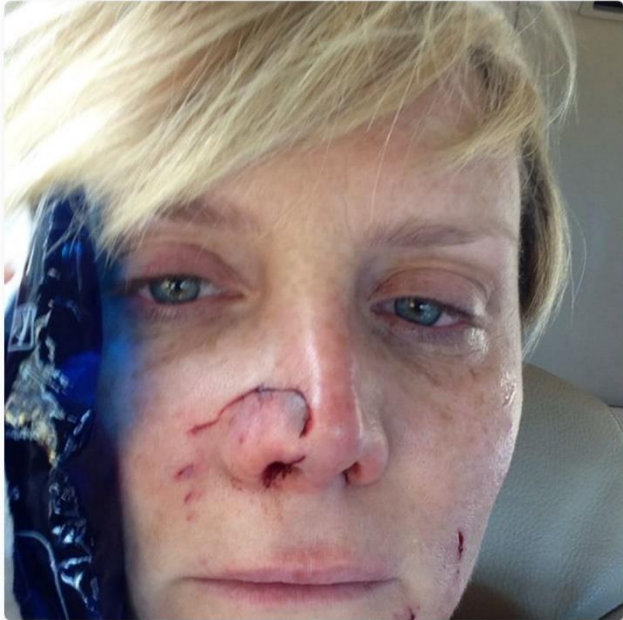Reconstrucción Nasal

No Touch

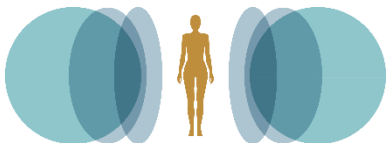
- Nueva Alternativa
- Injertos compuestos (Grasa, Cartilago, HA)
 - Regeneración tisular (ASC)
 - Estructura Y Soporte (grasa, cartilago)
 - Fácil distribución (Cánulas Curvas 25G)

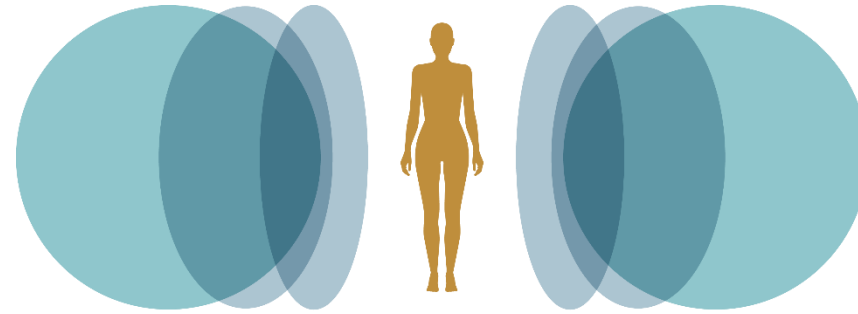
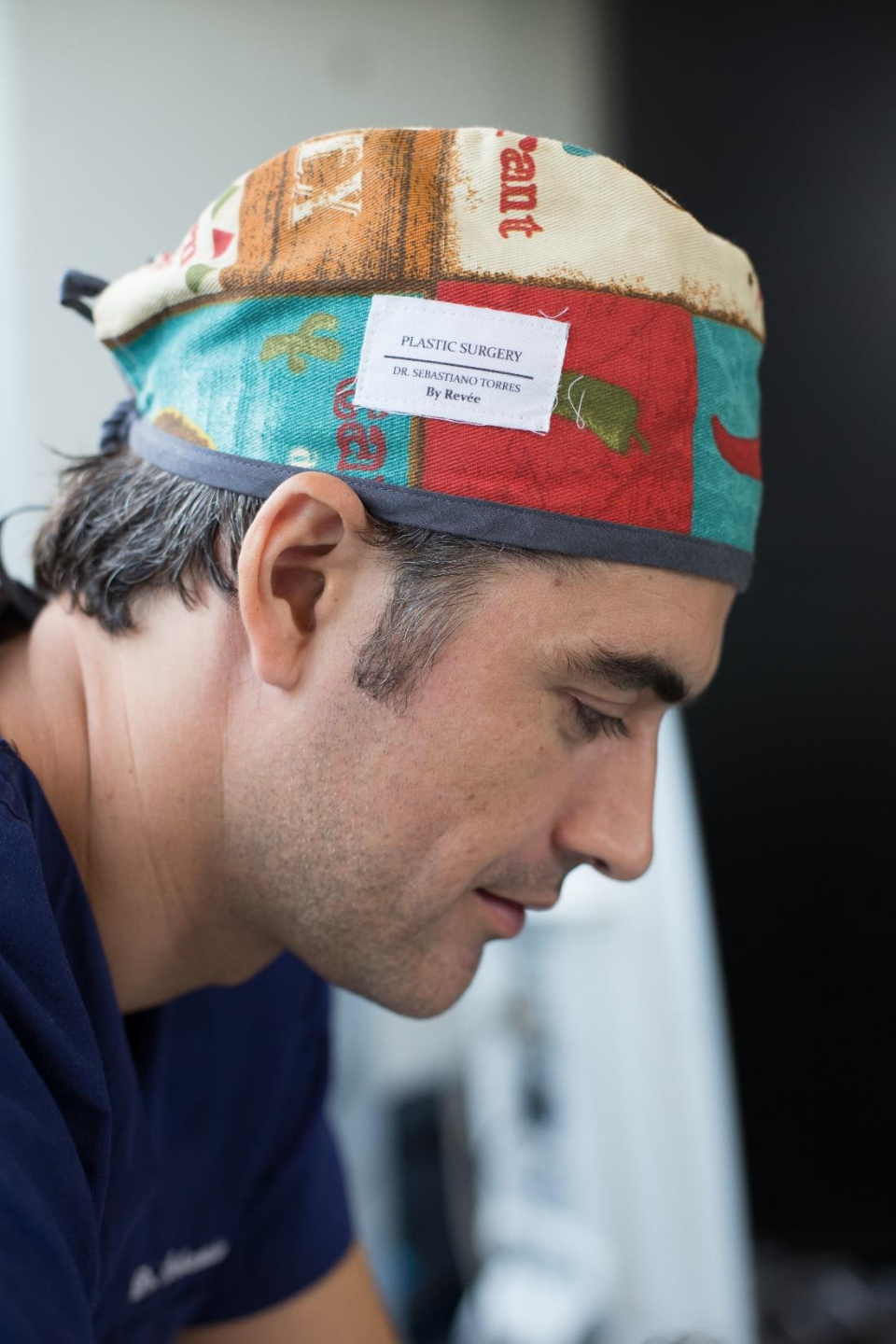





No TODO
es Reposición
Volumen...





Cirugía Integral 360°

DR. SEBASTIÁN TORRES

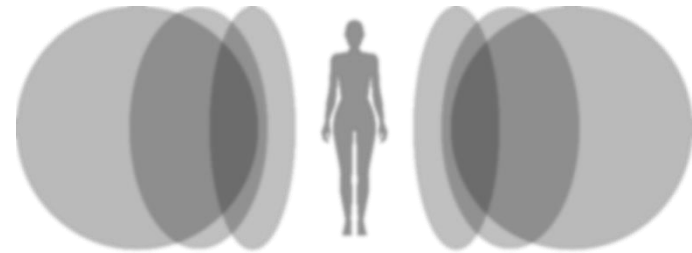
Follow me on:

 [sebastianatorresmd](#)

 [sebastianatorresmd](#)

 [sebastianatorres.cl](#)

Everything about the Nose: Aesthetics & Safety



Sebastian Torres MD